

## **Single Element In Obturation With Endodontic Retreatment With PBS® CIMMO Cement In Alveolar Tooth Abscess - Case Report**

Rubia Moura Leite Boczar<sup>1</sup>, Sérgio Ribeiro da Silva<sup>2</sup> Livia de Oliveira Alves<sup>3</sup>, Idiberto José Zotarelli Filho<sup>4</sup>, Jose Dias da Silva Neto<sup>5</sup>

<sup>1</sup>Fellow Master degree, Professional Master's Program in Applied Health, Universidade Vale do Sapucaí (UNIVÁS), Pouso Alegre-MG, Brazil. Conception, design, intellectual and scientific content of the study; acquisition, interpretation and analysis of data; manuscript writing.

<sup>2</sup> DS, Master degree, Professional Master's Program in Applied Health Sciences at the Sapucaí Valley University, UNIVÁS, Pouso Alegre, MG, Brazil. Conception, design, intellectual and scientific content of the study. Acquisition, interpretation and analysis of data. Manuscript writing.

<sup>3</sup> DS, Specialist in radiology, responsible for the study tomographies.

<sup>4</sup>São Paulo State University (Unesp), Institute of Biosciences, Humanities and Exact Sciences (Ibilce), Campus São José do Rio Preto/SP.

<sup>5</sup> DS, PhD, Associate Professor, Professional Master's Program in Applied Health Sciences, UNIVÁS. Conception, design, intellectual and scientific content of the study. Acquisition, interpretation and analysis of data. Manuscript writing. Critical revision of the study.

**Corresponding author:** Jose Dias da Silva Neto-Programa de Mestrado Profissional em Ciências Aplicadas a Saúde, UNIVÁS. Pouso Alegre-MG. Brazil. Av. Prefeito Tuany Toledo 470, Fátima I. Telefone: (035) 34499248 CEP: 37550-000, Phone #: 55 35 98883-6910, e-mail: [jdendod@yahoo.com.br](mailto:jdendod@yahoo.com.br)

### **Abstract**

**Objective:** Evaluation of tooth rehabilitation with chronic periradicular periodontitis, submitted to endodontic retreatment and filled with PBS® CIMMO cement as a single endodontic obturator element. As well as propose protocol change in endodontic obturation using biological cement without incorporation of gutta percha. **Methods:** Case Report: patient had a 3.7 tooth with conventional endodontic treatment and chronic periradicular periodontitis. Clinical examination revealed fistula and mobility. Initial tomography examination (Cone Beam tomography) determined the presence of extensive periradicular lesion. After removal of the intra-radicular nucleus, mechanical disbilling and chemical preparation of the root canal with continuous ultrasonic irrigation protocol (CUI) was performed. 5.5 % sodium hypochlorite and ethylene diamino tetraacetic acid surfactant were used as the auxiliary chemical. All channel filling was performed with PBS® biological cement. After six months, a clinical examination was performed. Absence of fistula and mobility was observed. The tomographic examination of preservation determined a decrease in the periradicular lesion. **Conclusion:** The protocol advocated in this case report determined reibilation of the tooth 37 and proposes further studies to establish a new biological obturator treatment for teeth affected by chronic periradicular periodontitis.

**Key words:** Root Canal Therapy, Endodontics, Biocompatible materials, Periapical Suppurative Periodontitis, Periapical Granuloma, Periodontitis.

## Introduction

The infected endodontium requires endodontic treatment for the purpose of eliminating microorganisms that infect the root canal and dentinal canaliculi. When conventional endodontic treatment is not able to rehabilitate the tooth, clinical signs appear [1]. In specific cases, there is absence of spontaneous pain and presence of fistula, drainage of purulent secretion and mobility. A periradicular lesion is detected by tomographic examination. Periradicular bone rarefaction is part of the immunological reaction of each patient and establishes itself as a defense. The greatest dimension of the periradicular radiolucency is directly proportional to the chronification of the endodontic infection and the intensification of periradicular periodontitis, having as synonyms: periradicular or periapical lesion, periapicopathies, periapical granuloma. The conical beam tomographic images determine the three dimensions of these lesions and the tomography is called Cone Bean [1,2,3].

The endodontic retreatment needs to supplant the initial endodontic treatment, determining a complex protocol for disbilling and elimination of microorganisms. In this way, the instrumentation requires the use of modern, rotating and reciprocating technological endodontic instruments; as well as auxiliary chemical substances: 5.5% sodium hypochlorite and ethylene diamine tetra acetic acid surfactant, associated to ultrasonic vibration (CUI) Continuous Ultra-sonic Irrigation, throughout instrumentation protocol [4,5,6,7].

Conventional root canal obturation follows a pattern that mixes gutta percha, an inert, plastic product, which makes up 70.0 % of the filling, and the remaining 30.0 % consists of cement. The cements evolved and currently, the scientific works that approach their properties as hermetic sealing and biocompatibility determined evolution. However, conventional filling does not alkalinize the endodontium definitively, the pH of the gutta percha / cement ensemble is not alkaline and are not precursors in the formation of carbonated apatites that promote biomineralization, attributes of biological cements [8,9].

The raw material for biological cements is limestone. Among them, the first one to emerge in dentistry was the MTA® (Agredado Trioxide Mineral), which in addition to the raw material is added bismuth oxide, a radiopacifying agent [8]. Studies have determined the development of a cement with the same base of MTA®, but with additives additions (natural elements responsible for cement resistance) and without

radiopacifier, an element that interferes with cement resistance, an important requirement due to the need to masticatory forces, called PBS® Cement (Pozolana Biologico Silva) [10,11,12,13].

The objective of this study was to evaluate the rehabilitation of a tooth with chronic periradicular periodontitis, submitted to endodontic retreatment and obturated with PBS® CIMMO cement as a single endodontic obturator element. The present study also proposes a protocol change in endodontic obturation using biological cement without incorporation of gutta percha.

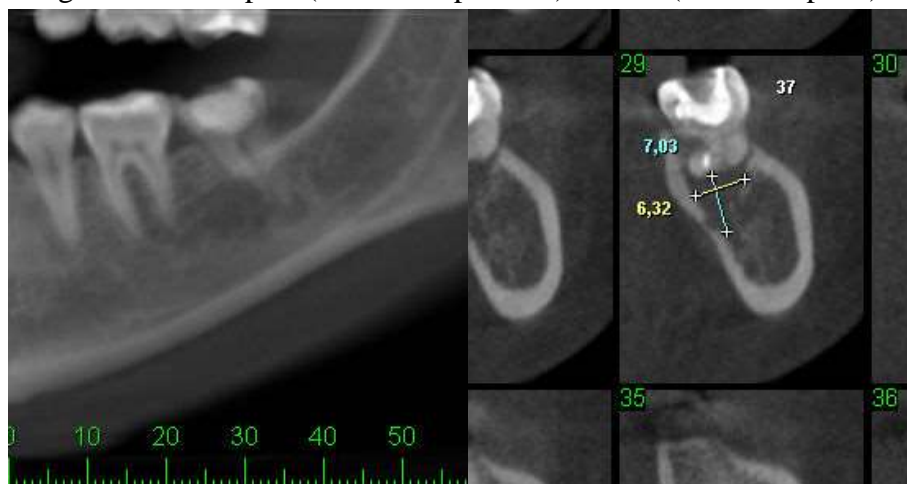
## **Methods**

### **Case Report**

The present study refers to a case report of chronic periradicular periodontitis involving tooth 37. Patient S., female, leucoderma, 32 years old. She was referred to the Dentistry Clinic of the Latvian Endodontics Specialization course at the Postgraduate Program at the University of the Sapucaí Valley, Pouso Alegre, Minas Gerais, Brazil. After being submitted to anamnesis, the need for endodontic retreatment was determined. The treatment was proposed to the patient. She then accepted and signed the Informed Consent (TCLE). In the clinical examination, a fistula with drainage and tenderness was observed in the tooth region 37 with palpation and vertical percussion. The tomographic images determined the presence of extensive periradicular lesion, which was measured (Figure 1).

The CT scan used was: CT-beam CT (Model i-CAT 17-19, Imaging Sciences International LLC, Hatfield, PA, USA). The long-axis dimensions of the lesions in the buco-palatal and coronal-apical directions were measured using CT images analyzed using the virtual navigation software Dental Slice (Bioparts Prototyping Biomedica, Brasília, DF, Brazil).

Figure 1 - Initial tomography of the tooth 37 that measures the size of the periradicular lesion at the greatest VP depths (vestibular-palatine) and IA (incision-apical).



### Interventions - Clinical procedure

Pterygomandibular anesthesia with anesthetic Articaine 1 / 100,000DFL® - Articaine hydrochloride + Epinephrine - 1 tube, with short hypodermic needle 30G Unoject®; absolute insulation of the operative field, using KSK® clamp number 14, Madeitex® rubber sheet. The first procedure to be performed was removal of the intraradicular nucleus with ultrasound; abundant irrigation with 2.5% Sodium Hypochlorite throughout the retreatment; Crown-down disintegration according to the apparent length of the tooth, Prodesign Easy® files 30.10 and 25.08 were used. Kerr Maillefer® manual files 20,25 in apparent length. The odontometry was performed through the NovApex® foraminal locator. Defining the working length and patency, the chemical-mechanical preparation was started. In the channels, Maillefer® Gates-Glidden drills number 2, 3 and 4 were used. The instrumentation was then started with Logic 25.05 Easy® files, which are Nickel-Titanium treated in a refractory porcelain kiln, with the aid of the Easy Endo SI from Easy®, the movement performed during instrumentation was "brushstroke". In the cervical and middle third of the 3 channels was used the file 25.05 with speed 950 rpm (revolutions per minute) and torque 4 Ncm (Newtons per centimeter). In the apical third, lime 25.05 was used with reciprocating movements and then rotational of 600 rpm in the working length.

To conclude this session, the final toilet protocol with ultrasonic agitation was performed using Gnatus® ultrasound and endodontic insert, using EDTA-T (17.0 % ethylenediaminetetraacetic acid with surfactant) of Formula e Ação® for 3 series of 30 seconds and abundant irrigation with Sodium Hypochlorite to 5.5 % and stirring thereof in 3 sets of 30 seconds. Final irrigation with distilled water. Drying with Tanary® absorbent paper cone. The channels were filled with unconventional PBS® cement. Cement manipulation was performed on Duflex® glass plate and spatula in "putty" consistency, the ratio of powder and water was 1/1, introduced with McSpadden's No. 40 Titanium Easy® drill bits in low spin and condensate Easy Pack® titanium condensers in green, black, yellow and blue. After the prey of the PBS cement was observed, the distal canal, Intra-radiucular pine Reforpost Angelus® was cemented. Restoration was performed in light-cured composite resin.

The prescribed systemic medication was: Amoxicillin 500.0 mg every 8 hours for 7 days, Dexamethasone 4.0 mg every 12 hours for 3 days and Dipyron Sodium 500.0 mg every 6 hours if there was pain.

The tooth and the surrounding tissues were evaluated after six months. The clinical examination showed no signs and symptoms such as edema, fistula, percussion pain and apical palpation pain. The scan image was evaluated by tomography (Figure 2). Measurements of the long-axis dimensions of the lesion were performed in the bucco-palatal and coronal-apical directions and compared with the measurements of the initial tomography.

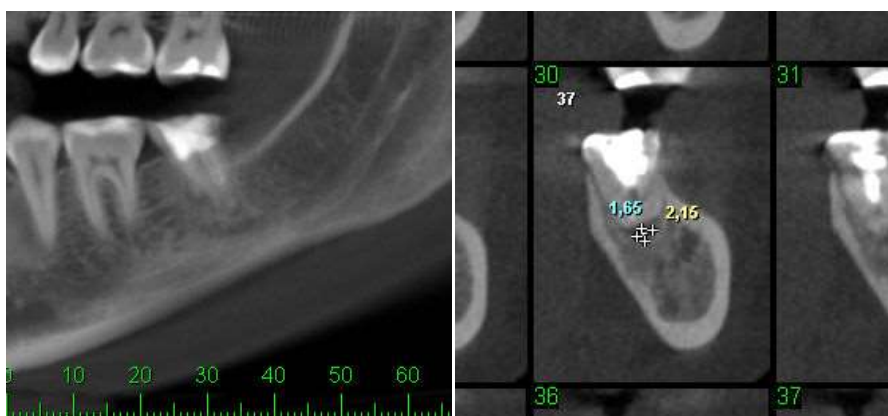## **Results**

Regeneration of the periradicular tissue was observed. Significant differences in the long axes of the lesion were found in the bucco-palatine direction and coronal-apical direction and are demonstrated by (Table 1).

Table 1 - Differences in the long axis measurements of the periradicular lesion in the coronal-apical and buccal-palatine directions at diagnosis (before) and 6 months after retreatment (in pixel).

	Before	After
VP	6,32	2,15
IA	7,03	1,65

Figure 2 - Tomography after 6 months of the tooth 37. Measurement of repair of the periradicular lesion at the depths VP (vestibular-palatine) and IA (incision-apical).



## Discussion

Chronic periradicular periodontitis is also called persistent as a result of having persisted to the initial endodontic treatment. Several factors contribute to this occurrence [14]. Among them, the failures are considered during modeling, sanitizing, cleaning and antiseptics maneuvers of the infected channels. Situations that are unfolding in instrumentation associated with conventional obturation that do not have bioactivity characteristics [15,9]. The association of causes determines the appearance of signs and symptoms that are: presence of fistula and drainage of purulent secretion, sensitivity to horizontal, vertical percussion and mobility.

The present study presented a case report with these conditions and aimed to perform endodontic retreatment. 5.5% Sodium Hypochlorite and Ethylene Diamine Tetra-Acetic Acid associated with continuous ultrasonic irrigation (CUI) were used after each instrument, in order to potentiate the antiseptic and degrading chemical action of organic and inorganic matter [16].

In addition to the mechanical ultrasonic chemical supplementation during instrumentation, 17 the present study performed obturation with biological cement as a single element [13]. The cement was installed without gutta percha. Conventional endodontic obturation consists of the association of endodontic cement with gutta percha cones. This procedure has become gold standard, however, the gutta-percha disposed in the shape of cones is inert material and represents 70.0 % of the volume of the obturation, the rest is composed of cements that have the function of connecting the gutta percha to the walls of the channel , making sealing of the empty areas around the gutta percha. The modern techniques advocated for this type of obturation require thermoplasticizing agents that heat the gutta percha cones and condense the gutta-cementum assembly towards the apical third of the canal [20]. In order to establish the technique so as not to overflow the obturator material to the periradicular region, radiographic procedures are required during the obturation process in order to calibrate the cones. This procedure requires attention, dexterity and time.

Most of the cements that accompany gutta-percha are not fully biocompatible, since the accuracy of no extravasation in obturation is questionable and may occur and cause chemical and traumatic pericementites. Although there are many studies on this technique and the cements incorporated into the cones, only a few are considered biocompatible. Resin cements such as AH Plus Dentsply® and calcium hydroxide base such as Sealapex Kerr® [18,19].

This so-called conventional shutter technique does not present the bioactivity requirement, present in biological cements today, this context is extremely important, due to the possibility of bioactivity to define definitive alkaline environment for the endodontically sealed. In this way, microbial proliferation in this environment would become impossible. Cases of persistent and secondary infection would have a greater chance of success if the environment of the endodontium did not remain alkaline [8].



The present study defined a protocol for the use of the biological cement PBS CIMMO as a single obturator, due to the conditions of the tooth diagnosed as chronic periradicular periodontitis [12,13]. The cement PBS composed the entire extension of the root and was extravasated, however, the absence of signs and symptoms and integrity of the tooth function were observed in the clinical examination of proservation. The tomographic images of proservation showed absence of radiopacity because this cement was designed to have no components that interfered in its biocompatibility and bioactivity.

Radiopacity is observed relative to that of the dentin and the aspect that the channels assume after being filled with PBS is of calcification of the root. Another aspect that requires discussion is the ease of the obturation technique when compared to the conventional one because it does not require measurements of cone or radiographs during the procedure, a fact that optimizes the operative time.

## **Conclusion**

Cone Beam scanning showed periradicular repair and the absence of signs and symptoms in the preservation and functional integrity of the tooth, demonstrate that this protocol of unconventional obturation can be more studied in works with larger casuistry.

## **References**

- 1-Ricucci D, Candeiro GT, Bugea C, Siqueira JF Jr . Complex Apical Intraradicular Infection and Extraradicular Mineralized Biofilms as the Cause of Wet Canals and Treatment Failure: Report of 2 Cases. J Endod. 2016 Mar;42(3):509-15. doi: 10.1016
- 2-Associação Americana de Endodontistas, "Glossário de termos endodônticos", 2012, <http://www.aae.org/glossary/>.



3-Del Fabbro M, Corbella S, Sequeira-Byron P, Tsisis I, Rosen E, Lolato A, Taschieri S. Endodontic procedures for retreatment of periapical lesions. *Cochrane Database Syst Rev.* 2016 Oct 19;10:CD005511.

4-Gorduysus MO, Al-Rubai H, Salman B, Al Saady D, Al-Dagistani H, Muftuoglu S. Using erbium-doped yttrium aluminum garnet laser irradiation in different energy output levels versus ultrasonic in removal of root canal filling materials in endodontic retreatment. *Eur J Dent.* 2017 Jul-Sep;11(3):281-286. doi: 10.4103.

5-Gorduysus MO, Al-Rubai KH, Al-Dagistani HS. Uso do laser na endodontia: um fato ou um mito? *ECronicon Dent Sci.* 2015; 3 : 123-5.

6-Fariniuk LF, Azevedo MAD, Carneiro E, Westphalen VPD, Piasecki L, da Silva Neto UX. Efficacy of protaper instruments during endodontic retreatment. *Indian J Dent Res.* 2017 Jul-Aug;28(4):400-405. doi: 10.4103.

7-Bhagavaldas MC, Diwan A, Kusumvalli S, Pasha S, Devale M, Chava DC. Efficacy of two rotary retreatment systems in removing Gutta-percha and sealer during endodontic retreatment with or without solvent: A comparative in vitro study. *J Conserv Dent.* 2017 Jan-Feb;20(1):12-16. doi: 10.4103/0972-0707.209075.

8- Torabinejad M, Parirokh M, Dummer PMH. Mineral trioxide aggregate and other bioactive endodontic cements: An updated overview- Part II: Other clinical applications and complications. *Int Endod J.* 2017 Aug 28. doi: 10.1111/iej.12843.

9-Gandhi B, Halebathi-Gowdra R. Comparative evaluation of the apical sealing ability of a ceramic based sealer and MTA as root-end filling materials - An in-vitro study. *J Clin Exp Dent.* 2017 Jul 1;9(7):e901-e905. doi: 10.4317.

10-Silva Neto JD, Brito RH, Schnaider TB, Gragnani A, Engelman M, Ferreira LM (2010) Root perforations treatment using mineral trioxide aggregate and Portland cements. *Acta Cirurgica Brasileira* 25, 479-84.

11-Silva Neto JD, Schnaider TB, Gragnani A, Paiva AP, Novo NF, Ferreira LM (2012) Portland cement with additives in the repair of furcation perforations in dogs. *Acta Cirurgica Brasileira* 27, 809-14.

12-da Silva SR, da Silva Neto JD, Veiga DF, Schnaider TB, Ferreira LM (2015) Portland cement versus MTA as a root-end filling material. A pilot study. *Acta Cirurgica Brasileira* 30, 160-4.

13-Silva SR, Silva JD Neto, Schnaider TB, Veiga DF, Novo NF, Mesquita M Filho, Ferreira LM (2016) The use of a biocompatible cement in endodontic surgery. A randomized clinical trial. *Acta Cirurgica Brasileira* 31, 422-7.

- 14- Vengerfeldt V , Mändar R , Saag M , Piir A , Kullisaar T . Estresse oxidativo em pacientes com patologias endodônticas. *J Pain Res.* 2017 24 de agosto; 10: 2031-2040. doi: 10.2147.
- 15- Pereira RS, Rodrigues VAA, Furtado WT, Gueiros S, Pereira GS, Avila-Campos MJ. Microbial analysis of root canal and periradicular lesion associated to teeth with endodontic failure. *Anaerobe.* 2017 Jun 27;48:12-18. doi: 10.1016.
- 16- van der Sluis LW. [Endodontics in motion: new concepts, materials and techniques 3. The role of irrigants during root canal treatment]. *Ned Tijdschr Tandheelkd.* 2015 Oct;122(10):533-8. doi: 10.5177.
- 17- Martins Justo A, Abreu da Rosa R, Santini MF, Cardoso Ferreira MB, Pereira JR ,Húngaro Duarte MA, Reis Só MV. Effectiveness of final irrigant protocols for debris removal from simulated canal irregularities. *J Endod.* 2014 Dec;40(12):2009-14. doi: 10.1016.
- 18- Kok D, Rosa RA, Barreto MS, Busanello FH, Santini MF, Pereira JR, Só MV. Kok D, Rosa RA, Barreto MS. Penetrability of AH plus and MTA fillapex after endodontic treatment and retreatment: a confocal laser scanning microscopy study. *Microsc Res Tech.* 2014 Jun;77(6):467-71. doi: 10.1002.
- 19- Akcay M, Arslan H, Durmus N, Mese M, Capar ID. Dentinal tubule penetration of AH Plus, iRoot SP, MTA fillapex, and guttaflow bioseal root canal sealers after different final irrigation procedures: A confocal microscopic study. *Lasers Surg Med.* 2016 Jan;48(1):70-6. doi: 10.1002.
- 20- Carpenter MT, Sidow SJ, Lindsey KW, Chuang A, McPherson JC 3rd. Regaining apical patency after obturation with gutta-percha and a sealer containing mineral trioxide aggregate. *J Endod.* 2014 Apr;40(4):588-90. doi: 10.1016.